

Research Article

Adoption of Geometric Properties to Detect Herniated Spinal Disc of Human

Sundos A. Al_Azawi, Israa Muhamad

Department of Computer Science, College of Science, Mustansiriyah University, IRAQ

*Correspondent Author Email: ss.aa.cs@uomustansiriyah.edu.iq

Article Info

Received
12 Mar. 2017

Accepted
12 Jun. 2017

Abstract

Image analysis and processing is useful in the medical images field, especially with the use of magnetic resonance images (MRI). In this research, MRI of the human's spine was analyzed and processed to identify and detect the herniated spinal Disc, or the probability of occurrence in the future. Lumbar and sacrum regions have been applied by the system. The system composed from three phases, the first is to identify the lumbar and sacrum regions, the second phase is the measuring of geometric properties, and finally the third phase is to detect the presence or the probability of herniated to occur in the future.

Keywords: Herniated spinal, Geometric properties, MRI.

الخلاصة

تحليل الصور ومعالجتها مفيد في حقل الصور الطبية، خصوصاً مع استخدام صور الرنين المغناطيسي (MRI). في هذا البحث، تم تحليل ومعالجة صور الرنين المغناطيسي للعمود الفقري للإنسان وذلك لتحديد والكشف عن انزلاق القرص الفقري الغضروفي، أو احتمال وقوعه في المستقبل. تم تطبيق النظام على مناطق أسفل الظهر والعجز. النظام يشمل ثلاث مراحل، الأولى هي تحديد مناطق أسفل الظهر والعجز، المرحلة الثانية هي قياس الخصائص الهندسية، وأخيراً للكشف عن وجود أو احتمال انزلاق قد يحدث في المستقبل.

Introduction

Computerizing medical image analysis and processing become one of the most important steps required to understand medical images and clarify what might hidden from undiagnosed medical condition.

Feature extraction in image processing is a special form of dimensionality reduction. Using computer technology in medical decision support is now widespread and prevalent across a wide range of medical regions such as spine, brain, cancer research, gastroenterology and etc. [1]. One of the most important and latest types of medical images is MRIs Spine [2].

MRI locates the physical changes that occur in a disc, inclusive the development of a herniation or bulge, that can lead to back pain, neck, or the development of radicular pain and numbness or tingling. From MRI, our healthcare provider can use various

information to decide the type and the location of disc herniation, or the damage that may have occurred and prescribe the suitable treatment, MRI is also a sensitive tool for the detection of spinal infections. [3]

In recent years, a research aimed to detect herniated in human spine for MRI based on features of the images by using different techniques and methods, Timor Kadir, Meelis Lootus, and Andrew Zisserman. They detect and labeled a Lumbar MRI by merging two strong algorithms that the deformable part model and deduction using dynamic programming on chains [4], Ales Vlasák, Dzenan Zukicy, Thomas Dukatz and Jan Egger, present a semi-automatic and fast approach for spine segmentation routine in clinical MR images [5], Michael Jorgensen, Naira Campbell-Kyureghyan, Deborah Burr and William Marras, validate and developed a

new method of predicting the neutral lumbar spine curve from external measurements [6].

Human Spine Structure

The spine is a bony structure in the middle of the human back, which extends from the skull to the pelvis and normally consists from 33 vertebrae. It is divided into five sections from the head to the hip by the following sequence: the cervical (C1...C7), thoracic or dorsal (T1...T12), lumbar (L1...L5), sacrum, and coccygeal spine as shown in Figure a. Figure b shows only lumbar zones. These latter are considered in this work which is in the low back area and consists of five vertebrae (L1...L5) and sacrum [7].

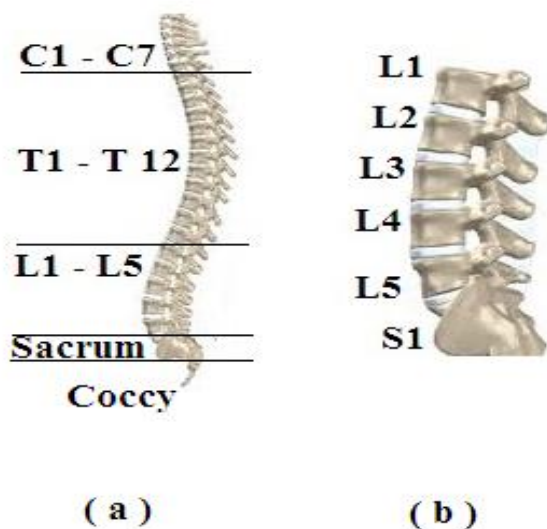


Figure 1: Human Spine Structure.

Lumbar Disc Herniation

Lumbar disc herniation or slipped disc founds in a lower back, it is a medical condition between the fourth and fifth lumbar or between the fifth and sacrum [8].

The intervertebral discs are tightly sandwiched between two discs in which they are attached. In normal case, Figure a shows two discs and their intervertebral without herniation disc. The disc is grown together with its adjacent disc and stretched all in small degrees. In disc herniation case in Figure b shows the changing of its degree value.

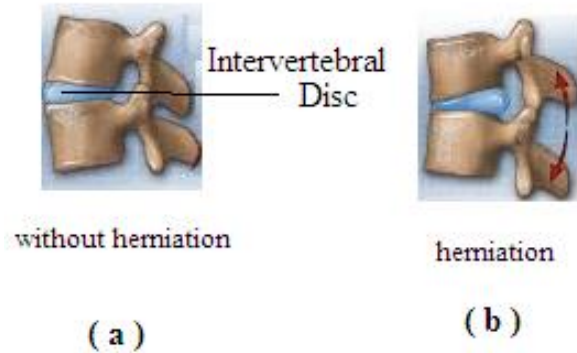


Figure 2: Lumbar disc herniation.

Magnetic resonance imaging (MRI)

MRI employs a radio frequency pulses. Powerful magnetic field and a computer to produce detailed pictures of organs: bone, soft issues, and nearly all other internal body structures that is clearer and more complete than other imaging methods. Magnetic resonance imaging (MRI) is an expanded medical test that doctors use to detect and treat medical conditions by evaluate different parts of the body, and determine the presence of certain diseases. Images can then be tested on a computer monito [1]. MRI data was used here because its quality is better than of X-rays. For determining the height of the intervertebral disc and the concavity of the vertebral endplates that only use the high-quality MRI data [4]. They are usually stored in the format called DICOM. The extension of the file is (image dcm). DICOM stands for Digital Imaging and Communications in Medicine.

Materials and Methodology

Proposed System

In this system, MRI was taken for the spine of human. Indeed, it selects a portion of the lumber of the spine and tries to detect the changes in the position of discs specifically, between fourth and fifth discs or fifth disc and the sacrum.

The detection of localized changes is by calculating geometric properties of the location for each disc and then compares those properties spaced periods of time for the same person.

It has been relying on this system on some

preprocessing method on digital images to get a boundary of each disc to detect regions in an image.

Discs Lumbar Selection

Algorithm (1) includes the steps that help to detect the discs regions. Then geometric distances were calculated for discs positions before and after spinal disc herniation.

Algorithm (1):

Input: MRI for Lumbar region in Human Spine

Output: Six regions (L1, L2, L3, L4, L5, and sacrum)

- Step1: Save MR Image by JPEG extension.
- Step2: Convert Lumbar region.jpeg into grayscale image.
- Step3: Enhancement grayscale image result to reduce high noise. Using median filter to reduce the noise from edges and lines in an image. It's work by replaces a pixel with median, and average of neighborhood pixels [9] [10].

$$Y[m, n] = \text{median}(x_{ij}), i, j \in w \quad (1)$$

Where w: is the neighborhood centered around location [m, n] in an image [11].

Step4: Segment the gray image using Thresholding method [10]:

$$T: g(x, y) = \begin{cases} 1, & \text{if } f(x, y) > T_0 \\ 0, & \text{Otherwise} \end{cases} \quad (2)$$

We'll get a binary image result.

Step5: From binary image, all white pixels are regions.

Step6: Determine the Position (x, y) for all pixels in each region.

Step7: All the objects surrounded by rectangle.

Step8: Determine the larger objects and adjacent by Common border, those are Lumbar discs (L1, L2, L3, L4, and L5) and last region that at bottom of fifth disc (L5) is a sacrum.

Implementation of Algorithm (1)

Figure show the six regions (L1, L2, L3, L4, L5, and sacrum) for Case1,

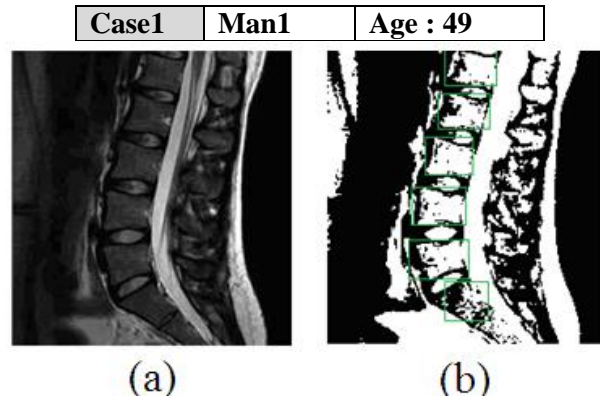


Figure 3: Discs Lumbar Selection. (a) Origin MRI , (b) Six Disc selection.

Geometric Properties Measurement

Algorithm (2) include the steps of calculate a geometric properties for lumbar discs, one of good methods is used of disc region center and the distance between adjacent discs. After applied preprocessing method on MRI spine, we have an objects, each disc represent an object.

Algorithm (2):

Input: six region (L1, L2, L3, L4, L5, and sacrum)

Output: Geometric angles properties

Step1: The centroid of region is the average of all the (x,y) coordinates in the region, Center pixel for L3, L4, L5, and sacrum was found.

Step2: scanning the image from the top until reaching the first white pixel (L1) limits

Step3: Draw a horizontal line through the white pixel in step 6, named H1.

Step4: Continued scanning the image to get to the last white pixel of the image (the lower border of the last region (sacrum)

Step5: Draw a horizontal line through the white pixel in step8, named H2.

Step6: Calculate a vertical distance (V) between H1 and H2 a horizontal lines, using Euclidean distance:

$$\text{Sqrt}((X_1 - Y_1)^2 + (X_2 - Y_2)^2) \quad (3)$$

Step7: Find a center pixel (CV) of vertical distance (V)

Step8: Measure a distance and Draw a line from CV into each Center pixel (step1) of discs (L3, L4, L5, and sacrum).

We have four distances:

D1= L3:CV, D2 = L4:CV, D3 = L5: CV, and D4 = sacrum: CV

Step9: Measure the angles between each two adjacent lines (D):

$$\vartheta = \text{Tan}^{-1} = \frac{m_1 - m_2}{1 + m_1 m_2} \quad (4)$$

in our case, m = D,

We have Three Angles: A1 ϑ (D3, D4), A2 ϑ (D4, D5), and A3 ϑ (D5, D6)

Step 10: Save the result from step 13 into database.

Implementation of Algorithm (2)

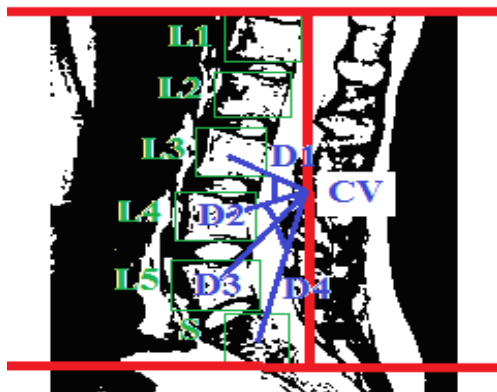


Figure 4 shows the geometric properties for case1, where D1, D2, D3, and D4 are distances between CV (center pixel of vertical distance (V)), and the centroid of each (L3, L4, L5, and S (scram)). Three angles was found among (D1:D2, D2:D3, and D3:D4).

Case1	Man1	Age : 49
-------	------	----------

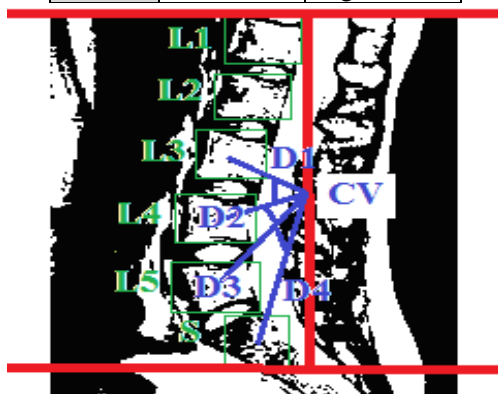


Figure 4: Measuring of Geometric Properties for Case1.

Input: Read MR Image.

Output: Detect the herniated.

Step1: Applied Algorithms (1 and 2) to measure geometric properties for new MRI input for same person, so we have new three angles: B1 ϑ, B2 ϑ, B3 ϑ. Where B: new angle.

Step2: Compare geometric angles properties from step 1 within geometric angles properties saved in database for same person:

For each angle (A and B) do:

$$\text{Def1} = \|A1 \vartheta - B1 \vartheta \|, \text{Def2} = \|A2 \vartheta - B2 \vartheta \|, \text{and Def3} = \|A3 \vartheta - B3 \vartheta \|$$

Where: Def1 is the deference between two angles (A and B).

Step 3: between adjacent discs:

If (0.9mm > Def. > 0.5mm) then High probability occurrence of Herniated.

If (0.4mm > Def. > 0.0mm) then low probability occurrence of Herniated.

If (Def. > 0.9mm) then Herniated was found.

If (Def. = 0) then no Herniated in it.

Results and Discussions

In this work, the objective is to study various cases from persons aged between 45-60 years. This is because the herniated disc usually begins in this age group. Parts of the spine have been selected with portion of the Lumbar with sacrum.

In proposed system algorithms, we will rely on the angles that have been measured based on discs position. Samples were taken from the MRI of the same person from periods far apart (two per person) and the comparison between the angles at natural state with the angles in an ongoing suspicion of herniated. So far, it is resulting with the numeric value that determines the presence or the absence of herniated between two adjacent discs.

Three algorithms are applied to Case2, Man2 was selected, geometric properties measured in the system for the first time to get MRI of the person was 54 years of age, and then the properties stored in the database until the need for them to help in the detect herniated spinal. The second time for the same case (Case2) was

the person's age 56 was measured geometric properties of the MRI its own.

Discs Lumber Selection

For Case 2, Figure 1 shows the six regions (L1, L2, L3, L4, L5, and sacrum) on two periods of MRI1 and MRI2.

Case2	Man2	MRI1	Age: 34	MRI2	Age: 56
-------	------	------	---------	------	---------

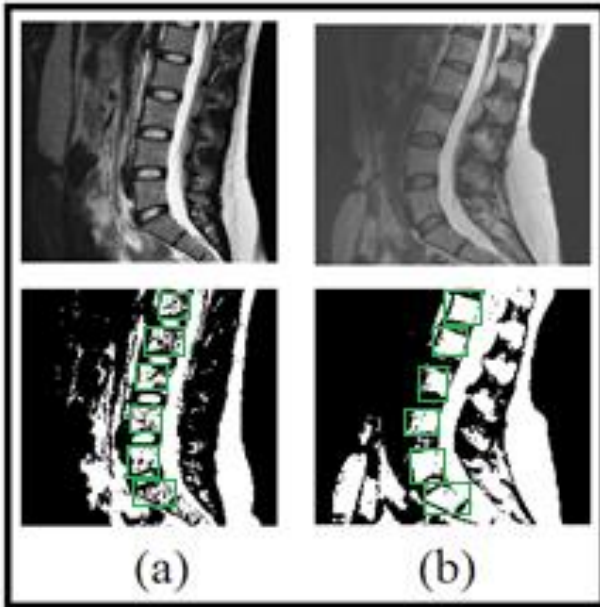


Figure 1: Discs Lumber Selection. (a) Origin MRI1 and Six Disc selection, (b) Origin MRI2 and Six Disc selection.

Geometric Properties

Figure shows the measure in two periods of case geometric properties of his MRI1 and MRI2.

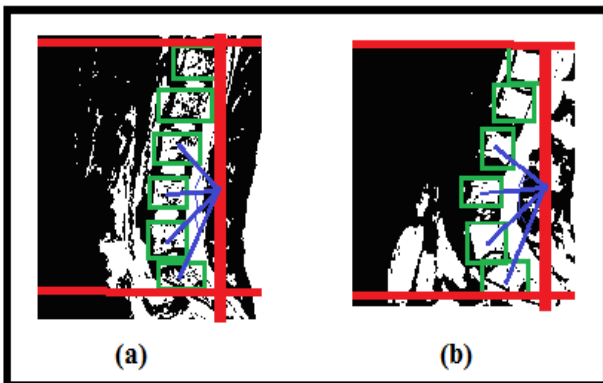


Figure 6: Measuring of Geometric Properties for Case2 (a) Geometric properties for MRI1, (b) Geometric properties for MRI2.

Herniated Detection

In order to implement the third algorithm in the Herniated detection, we were used the properties extracted from the second algorithm of Case2.

Table and Figure show the value of the angles and the difference among all the angles in the same area, depending on the magnetic resonance images of the same case.

Table 1: Herniated Detection in Deference Angles.

Angle MRI1	Angles Degree	Angle MRI2	Angles Degree	Deference (A and B)
A1	14.3	B1	14.9	0.6
A2	13.1	B2	12.8	0.3
A3	20.5	B3	19.2	1.3

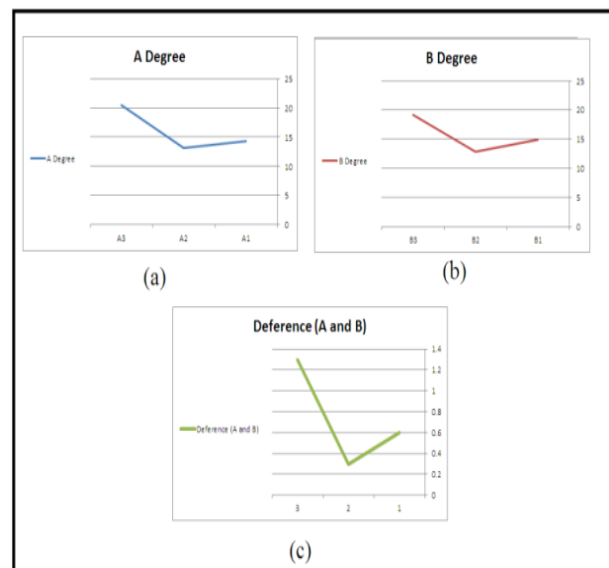


Figure 7: Measuring of Geometric Properties for Case2.

In Figure a, three angles (A1, A2, and A3) were extracted from MRI1 from Case2. Figure b, three angles (B1, B2, and B3) were extracted from MRI2 from Case2. The difference between the two angles (A and B) are shown in Figure c. We can clearly found a Herniated between L5 and Scram (where Def.= 1.3mm). High probability occurrence of Herniated between L4 the third and L3 (if Def. > 0.5mm), but less likely to occur a Herniated between L4 the third and L3 (if Def. < 0.5mm).

Conclusions

In this paper, we proposed a system which measure geometric properties for detecting a Herniated in the Lumbar discs of the spine human. This latter can used to detect Herniated Spinal Disc or the likelihood of its occurrence in the future. It has been relying on the analysis and processing of medical images of the type of MRI that give clear details of the member. Before starting the process of measuring the properties had to be undergoing preprocessing methods such as converting the image to gray system and optimize images for the best result. Geometric properties such as distances and angles between adjacent discs will be considering in detection of Herniated stage of the system. Detection of Herniated in the Lumbar discs was determined by difference between same angles location for same person but in different two periods.

In future, we can reuse the results from this system for other parts of the spine, or in the detection of bone fractures. We can also rely on the other properties of the images such as texture.

References

- [1] E.I. Papageorgiou, P.P. Spyridonos, D. Th. Glotsos, C.D. Stylios, P. Ravazoula, G.N. Nikiforidis, and P.P. Groumpos, " Brain Tumor characterization using the soft computing technique of fuzzy cognitive maps," *Applied soft computing*, pp. 820-828, 2008.
- [2] V. D. R., "Managing DICOM images: Tips and tricks for the radiologist," *Indian J Radiol Imaging*, 2012.
- [3] A. C. Douglas, *Fundamentals of Spine MRI and Essential Protocols*, MD: Akinwande, 2009.
- [4] M. Lootus, T. Kadir, and A. Zisserman, *Vertebrae Detection and Labelling in Lumbar MR Images*, Oxford University.
- [5] D Zukic, C. Nimsky, A. Vlasak, T Dukatz , D. Horinek and A. Kolb, "Segmentation of Vertebral Bodies in Mr Images," *Vision, Modeling and Visualization*, 2012.
- [6] N. Kyureghyan, D. Burr, M. Jorgensen, W. Marras, " The prediction of lumbar spine geometry: method development and validation," *Clinical Biomechanics*, 2005.
- [7] Dutton, *Orthopaedics for the Physical Therapist Assistant*, Jones & Bartlett., 2012.
- [8] P. Nigel, and Roger W. Soames, *Anatomy and Human Movement: Structure and Function*, Churchill Livingstone, 2012.
- [9] Sumaya, and Zena Vatsa, "MRI Image Enhancement," *International Journal of Science and Research*, 2013.
- [10] Gonzalez R. C. and Woods R. E, "Digital Image Processing," University of Tennessee, 2000.
- [11] I. R. 2. C. V. Company, " Mathematical Morphology and Distance Transforms," Centre for Image Analysis Swedish University of Agricultural Sciences, Uppsala University, 2013.